

## Optic Disk Detection in Retinal Images – Evaluation

Mrs. R. Sharmiladevi <sup>1</sup>, Mr. G. Sathish kumar <sup>2</sup>

<sup>1</sup>M.E, Department of Computer Science and Engineering, MNSK College, Pudukottai, TamilNadu, India.

<sup>2</sup>Asst.Professor, Electrical Communication Engineering, MNSK College, Pudukottai, TamilNadu, India.

[Sharmila.infotech@gmail.com](mailto:Sharmila.infotech@gmail.com)

### Abstract:

In retinal image analysis, the detection of optic disc is of predominant importance. It facilitates the trailing of varied anatomical choices and to boot within the extraction of exudates and drusens etc., gift within the membrane of human eye. The health of membrane crumbles with age in some people throughout the presence of exudates inflicting Diabetic Retinopathy. The existence of exudates can increase the prospect for age connected degeneration (AMRD) and it is the leading cause for disablement in people on high of the age of fifty. A prompt diagnosis once the illness is at the primary stage can facilitate to prevent irreversible damages to the diabetic eye. Screening to watch diabetic retinopathy helps to prevent the visual loss. The point detection is that the rudimentary demand for the screening. Throughout this paper few ways in which for point detection were compared that uses every the properties of point and model based approaches. They are unambiguously accustomed supply correct lands up within the retinal footage.

**Keywords:** Diabetic Retinopathy, macular degeneration, exudates, retina, optic disk.

### I.INTRODUCTION

Diabetic Retinopathy (DR) may be a results of long term DM. it's been noted as a significant growing public unhealthiness. It is one of the predominant causes of visual disorder. It causes pathological changes of the tissue layer like microaneurysms, intraretinal microvascular abnormalities, blood vessel injury and neovascularities as well as haemorrhages, exudates and retinal oedema. Regular screening of Diabetic Retinopathy is indispensable in order that acceptable and timely treatment may be given that thereby reduces the incidence of impaired vision and visual disorder from this condition. Current ways of detection and assessment of diabetic retinopathy area unit manual, expensive and need extremely trained personnel to read sizable amount of anatomical structure pictures. The potency can be improved by automating the primary task of analyzing the massive quantity of retinal anatomical structure pictures.

The optic disk is that the brightest half in bodily structure images which will be seen as a pale, spherical or slightly oval disk. It's the doorway region of blood vessels and conjointly acts as a landmark and reference for the other options within the bodily structure image. There are many methods for point detection.

In the Principal Component analysis methodology (PCA), the minimum distance between

the first retinal image and its projection onto space is found because the center of Optic disk. This detection is correct however a lot of time intense. Within the next methodology PCA and active shape model is employed, wherever the form of the OD is obtained by a vigorous form methodology. Here the affine transformation is employed to remodel the form from form area to the image area. This formula takes the advantage of prime down process that increases the strength however it's time intense. In lab colour morphology, the location of point was by each the automated data format of snake and the function of morphology in colour space.

In Sobel edge detection and least sq. regression, the detection is performed within the red component in steps-candidate space identification, sobel edge detection and estimation step. Lalonde et.al used a Hausdorff-based template matching technique edgy map, guided by a pointed decomposition for massive scale object chase. The cholesky algorithm was used but the snake had didn't find the boundary in the higher right quadrant. during this paper, the detection of point is completed victimisation combination of assorted concepts. at first the candidate regions are elite and by victimisation totally different ways like iteration, binary imaging, clump and PCA, propagation through radii, the placement of point is detected and compared.

## II. METHODS

### 2.1 CLUSTERING

This is a distance based mostly technique. The calculation of threshold is completed by easy mean estimation technique and multiplying the mean image by a scaling issue. A scaling issue of zero.85 is appropriate. the grey scale image is at first scanned element by element. for each element extraordinary the threshold a box of size (5 x 5) is made. This box is named a cluster. The x and y coordinates of the element is updated into 2 vectors row and column. ranging from the primary entry within the vectors a box with coordinate lying in a suitable level of distance is searched. To figure the distance basic mathematical formula

$$\sqrt{(x_2-x_1)^2+(y_2-y_1)^2} \text{ ----- (1)}$$

is used. Once found the boxes square measure joined. The boxes square measure joined supported their location.

Say for instance, (x1, y1) be the center of mass of initial cluster and (x2, y2) be the center of mass of second cluster. when this the fundamental mathematical formula to evaluate the gap between 2 points is applied to find out the gap between the clusters. Keeping (x1, y1) because the reference the gap between this reference and also the center purpose of each other cluster is decided. The clusters having centroids inside a nominative distance from this reference center of mass purpose area unit combined. The northwest point of the reference cluster and also the Southeast point of the cluster that is nearer thereto area unit merged to create one cluster. Then afterwards these centroids area unit far from the list of centroids to be evaluated. This development is repeated for each alternative canter of mass and also the clusters area unit regrouped. This technique is perennial on top of for certain time which provides bound candidate regions. For every candidate, range of pixels surpassing the threshold is found. If it's below a particular level determined by the scale of the candidate region the candidates area unit discarded. Finally we have a picture in which the candidate region utterly encloses the point although it should not precisely sq. it.

This is appropriate for traditional healthy fundus pictures wherever in point is alone the brightest region of the image. however our pictures contain exudates and lesions. The exudates intensity worth is analogous thereto of point. If it is small in size then it will be characterised by the intense pixels density. however in some pictures the exudates are as huge

and thick as exudates. In such cases it's tough to seek out that of the candidate contains the point.

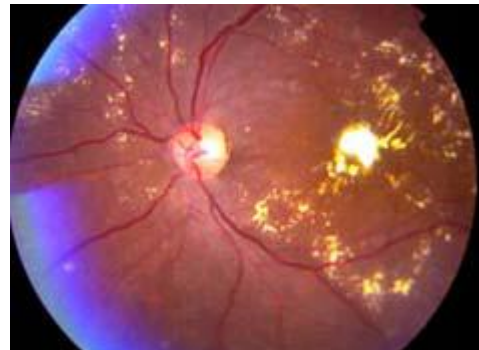

Figure 2.1 ABNORMAL INPUT IMAGE

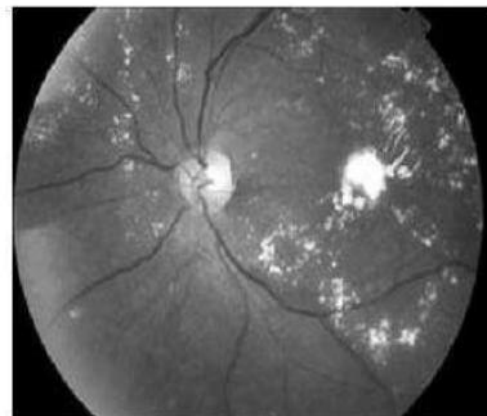


Figure 2.2 Grayscale Image

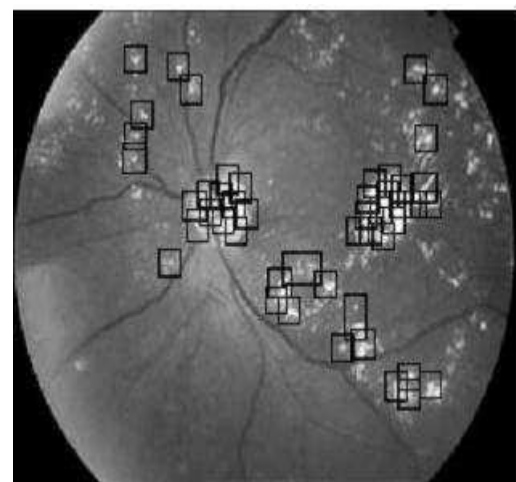


Figure 2.3 First Stage Clustering Image

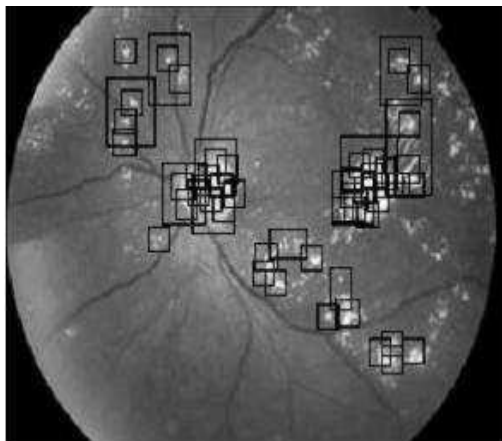


Figure 2.3 Second Stage Clustering Image




Figure 2.4 Third Stage Clustering Image




Figure 2.5 Fourth Stage Clustering Image

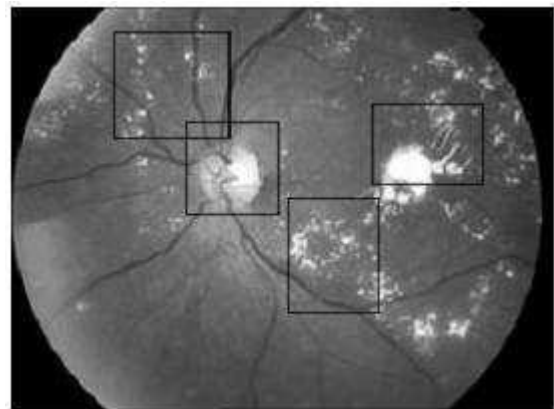


Figure 2.6 Penultimate Stage Clustering Image

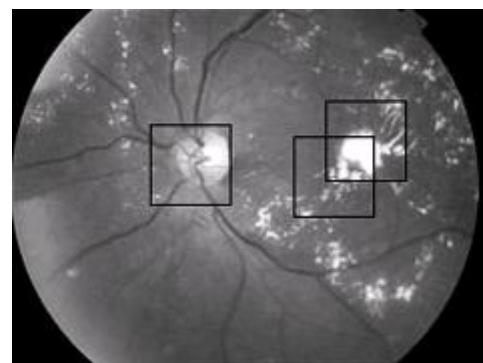


Figure 2.7 OUTPUT Of CLUSTERING

## 2.2 PRINCIPAL COMPONENT ANALYSIS (PCA) BETWEEN CLUSTERS:

PCA may be a statistical system. For every pixel a window is built around it with the pixel because the center. For every box PCA is applied and the one having minimum euclidean distance contains point. Our take a look at image size is 240 x 180. So the

PCA method should be applied 43200 times. Therefore it's terribly time intense and also the technique is not correct enough to attend farewell. Clustering does not show correct output for pictures with exudates. The advantage of the PCA and agglomeration can be combined. the most extract of this technique is that, the candidate regions are 1st determined by clustering the brightest pixels in application image. Principal element Analysis is then applied to these candidate regions. The candidate region having the smallest amount Euclidean distance contains the optic disc. Through the centre of the candidate region and centre of the point doesn't coincide, the region encloses the point.

The Candidate region is decided by clustering technique. The agglomeration technique produces different range in candidate regions. But for applying PCA we want the candidate regions to be of mounted planned size. (40 x 40) in our case, so the candidates square measure resized. for each mounted size cluster we discover the brightest element and construct a forty x 40 box.

The mounted size clusters and these boxes square measure the entries for PCA. Thus if there square measure n candidates we will have 2n PCA entries. currently we tend to apply PCA only to those entries instead of to each box centered around each pixels of the image. The training set are often extracted one by one by moving a window of size forty x40 over this single image. These extracted sub pictures square measure keep in a very 3 dimensional matrix. therefore the dimension of this matrix represents a page and every page contains a individual sub image. By doing this the access of the individual sub pictures becomes straightforward as they have identical name and solely differs within the index of the dimension that may be a numerical price. By incrementing this numerical price in a very for loop, the consecutive sub pictures that type the coaching dataset are often accessed.

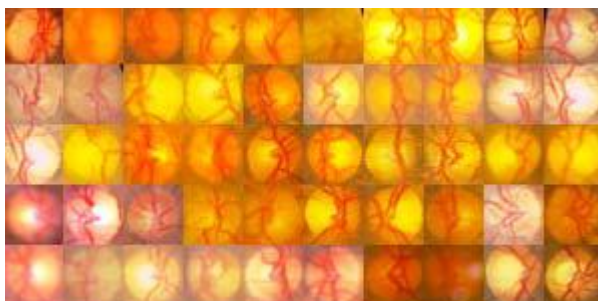


Figure 2.3 guiding image

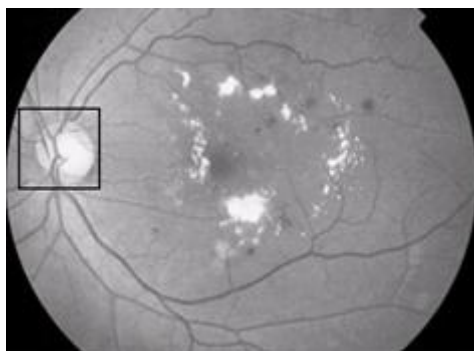


Figure 2.4 OUTPUT USIN PCA METHOD

### 2.3 PROPAGATION DURING RADII

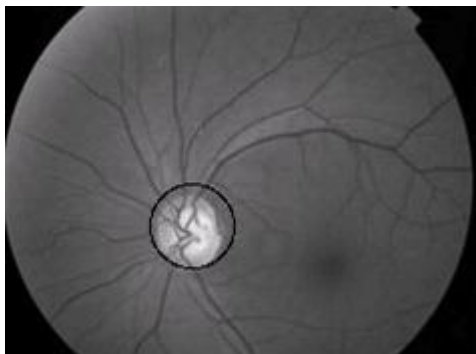PCA between clusters produces output specified the point is confined during a square box of size (40 x 40). For fastened size boxes 1600 pixels square measure extracted considering it to be containing the point. However in several pictures the optic disc occupies solely around one thousand pixels. If any exudates lie at intervals proximity of the point then it may even be extracted. This could increase the chance of abnormal tissue layer being described traditional.

In few images the point is just too giant to utterly work within the (40 x 40) box. Thus few of the point pixels might stay un extracted. This could intervene in exudate detection. Thus in either case extracting pixels underneath a hard and fast size space isn't economical. To avoid this we have a tendency to try to outline a circle (circle of best fit) that encloses the point with minimum number of pixels that doesn't belong to the optic disc. the initial body structure image is subjected to contrast restricted adaptation bar chart deed.

The centre of the box containing optic disc is outlined by coordinates (A, B). Normally to represent a circle in distinct house we have a tendency to use  $A+r\cos\theta$ ,  $B+r\sin\theta$ .  $\theta$  lies from zero to 360. The discretionary initial value of r is ten. so we have got  $(\{A+10\cos0, B+10\sin0\}, \{A+10\cos1, B+10\sin1\} \dots \{A+10\cos360, B+10\sin360\})$ . every of them representing some extent within the circumference of the circle. Currently the primary purpose (corresponding to  $\theta=0$ ) on the circumference is taken. Keeping it because the Centre point and a picture element is chosen higher than  $(A+(r+1)\cos\theta, B+(r+1)\sin\theta)$  and below  $(A+(r-1)\cos\theta, B+(r-1)\sin\theta)$  that. The distinction of picture element intensity worth between the higher purpose and center purpose and conjointly between lower purpose and center purpose is computed.

A threshold is about (5 in our case) and if the distinction value is larger than the brink create the middle point is formed black. This procedure is perennial till the distinction worth becomes larger than the threshold, whenever shifting the centre purpose upward on the radius by incrementing the initial r value .The final r worth is that the radius corresponding to that  $\theta$ . this is often in dire straits all the points gift in the circumference of the circle i.e., for  $\theta$  go from zero to 360. Thus we have a tendency to get radius for all 360 degrees, then the

mean radius is found. Our next step is to search out mean centre. this is often done by finding point of line connection circum points of supplementary angles for  $\theta=0$  to one hundred eighty. The mean of these x and y co-ordinates of the midpoints offers United States of America the mean centre. The circle of best work is drawn with mean centre because the centre and mean radius because the radius. As error margin may be intercalary to the mean radius, this ensures that the optic disk is totally



**Figure 2.5** OUTPUT USING PROPAGATION THROUGH RADII

### CONCLUSION

Scaling agency of 0.85 is adapted in clustering method and is acceptable for accustomed advantageous images where optic disc is the brightest arena in the image. Using PCA amid clusters, out of 50 images, authentic after-effects are acquired for 44 images. The apprehension of exudates involves the abatement of optic disk. Under these affairs propagation through radii adjustment can be employed. The various methods for optic disc apprehension is accustomed in which the time burning of PCA is affected by applying PCA alone to the clusters. The propagation through radii adjustment is acceptable for removing optic disc in the apprehension of exudates back it does not require the exact centre of optic disk.

### REFERENCES

- [1] Li, H. and Chutatape, O.(2001) 'Automatic location of Optic Disc in Retinal Images ', IEEE ICIP, pp.837- 840.
- [2] Li, H. and Chutatape, O. (2003) ' A Model – based approach for Automated feature extraction in fundus images ', proceedings of the 9th IEEE International Conference on Computer Vision.
- [3] Osareh, A, Mirmehdi, M, Thomas, B. and Markham, R, (2002)' Color Morphology and snakes for Optic Disc Localisation ', the 6th Medical Image Understanding and analysis Conference.

- [4] Osareh, A, Mirmehdi, M, Thomas, B. and Markham, R, ' Comparison of Colour spaces for Optic Disc localization in Retinal images'Pattern Recognition, 2002. Proceedings. 16th International Conference, volume1, pages:743-746.
- [5] Li, H. and Chutatape, O.(2000) Fundus image features extraction ', Proceedings of the 22nd Annual International Conference of the IEEE Engineering in Medicine and Biology Society, Vol.4, pp.3071-3073.
- [6] Lupascu, C.A, D.Tegolo and L. Di Rosa,'Automated Detection of Optic Disk localization in Retinal images', Computer-based medical System, 21st IEEE Int.Symp., 17- 19:17-22
- [7] Lalond, M, Beaulieu, M. and Gagnon, L. (2001) 'Fast and Robust Optic Disc Detection using Pyramidal Decomposition, IEEE Transactions on Medical Imaging, Vol.20, No.11:1193- 1200
- [8] Morris, D. T. and Donnison, C.'Identifying Neuro Retinal Rim Boundary Using Dynamic contours',Image Vision Computing,17(3-4):169-174.